

Irish Wolfhound Health Group



Dentition Study

In September 2014, the IWHG launched an observational Dentition Study. This was as a result of:

- (a) an apparent rise in canine orthodontic referrals (especially for young puppies)
- (b) the Kennel Club's inclusion of "misplaced lower canines" as the only "Breed Watch" point for Irish Wolfhounds



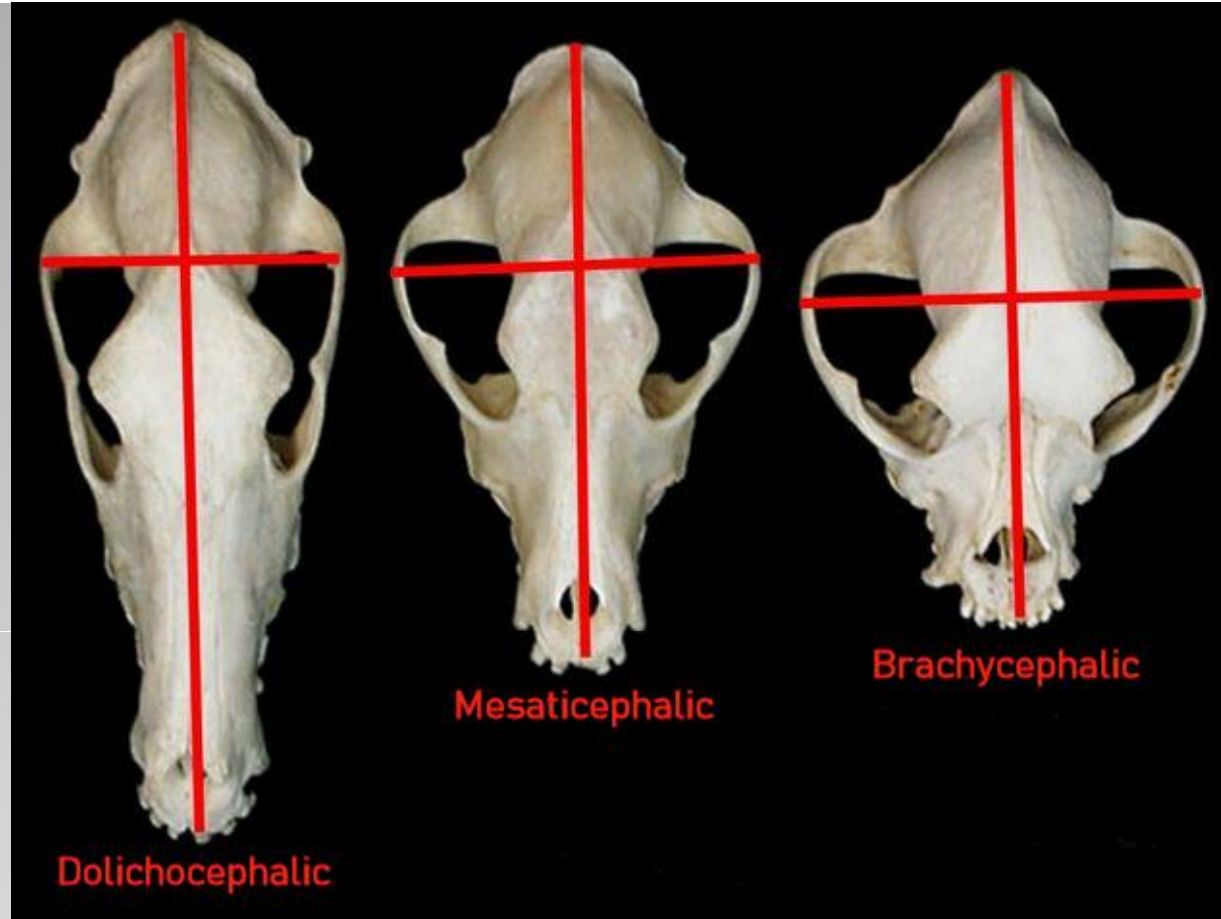
IWHG – Dentition Study INTRODUCTION



*This presentation isn't intended to dispute the findings of veterinary dental specialists, in respect of the **average** dog*

POINTS TO CONSIDER

- Wolfhounds are rapidly growing giant sighthounds, who rarely reach full maturity before 3 years of age.
- Their growth doesn't conform to the pattern seen in medium sized dogs with medium length muzzles.
- An Irish Wolfhound puppy's weight can increase by 100 times, from birth to 6 months, so their entire skeletal and muscular development, doesn't fit within average parameters.



- Dolichocephalic – long and narrow headed
- Mesaticephalic – medium headed
- Brachycephalic – short headed



IWHG – Dentition Study



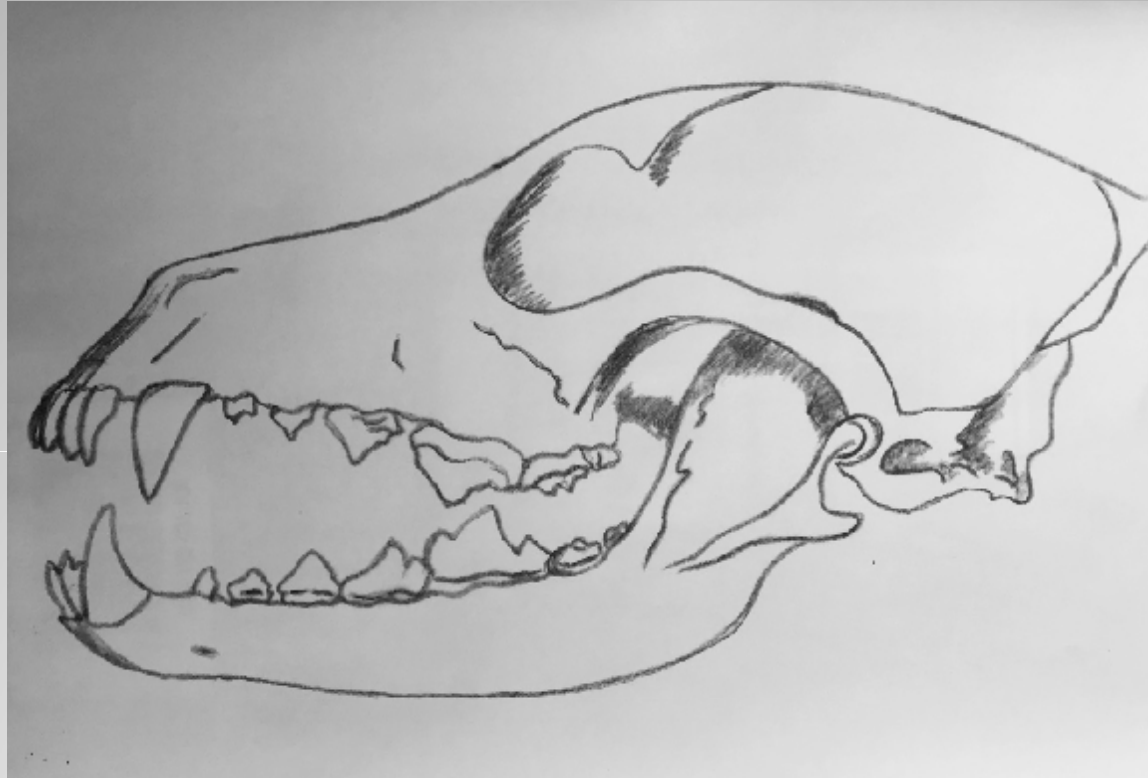Irish Wolfhounds' heads are considered to be **dolichocephalic** with the muzzle typically being longer than the back skull

The “average” shaped dog head, is **mesaticephalic** (*sometimes referred to as mesocephalic*) with the back skull & muzzle (*head and foreface*) being more or less equal in length

Breeds with a short, or virtually absent, muzzle are known as **brachycephalic**. Their development is accepted as **not conforming to what is considered average or usual**

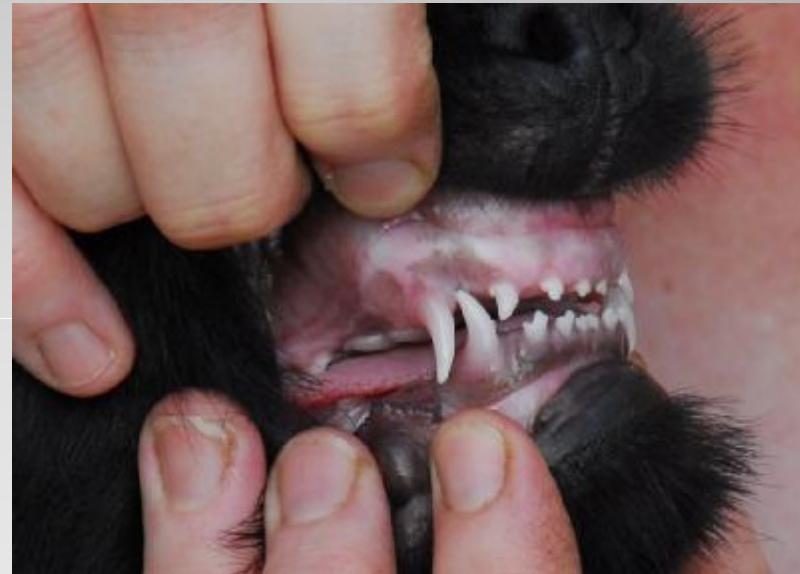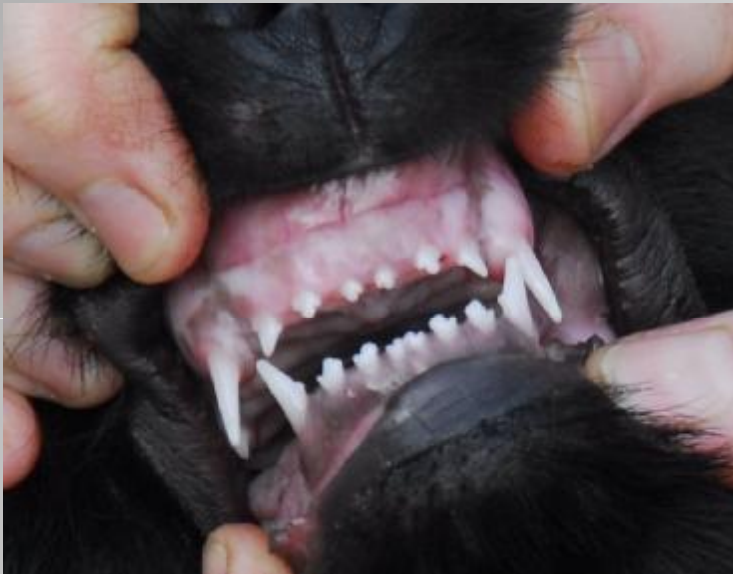So surely a breed that is not only **dolichocephalic**, but also a **giant**, with a **rapid** and **prolonged** growth, should be afforded similar consideration, being outside the “norm”.

- Occlusion – the way teeth and jaws meet



- Maxillary – relates to the upper jaw
- Mandibular – relates to the lower jaw

Lingual – towards the tongue
Buccal – towards the cheek



Mesial – the front of the tooth
Distal – the back of the tooth

SCISSOR BITE

- A “normal” correct occlusion, referred to in breed standards as a “scissor bite”, will have the upper incisors slightly overlapping the lower

and

- the mandibular canines set in front of the maxillary, when the mouth is closed

The puppy on the previous slide has a good occlusion

- Jaws more or less the same width and length
- Incisors meeting in a scissor bite
- Lower canines angled buccally (towards the cheek) and correctly positioned, mesial (or rostral) to the upper
- Lower canine fits neatly in the diastema (the space) between the maxillary canine and lateral incisor

MALOCCLUSION

any deviation from what is considered a normal scissor bite

- This may be due to skeletal influences

or

- the abnormal positioning of a tooth or teeth

Lingually displaced lower canines





IWHG – Dentition Study



Lower canines that are lingually displaced (*also called "linguoverted" or "base narrow"*) are incorrectly positioned teeth, leaning towards the tongue instead of the cheek

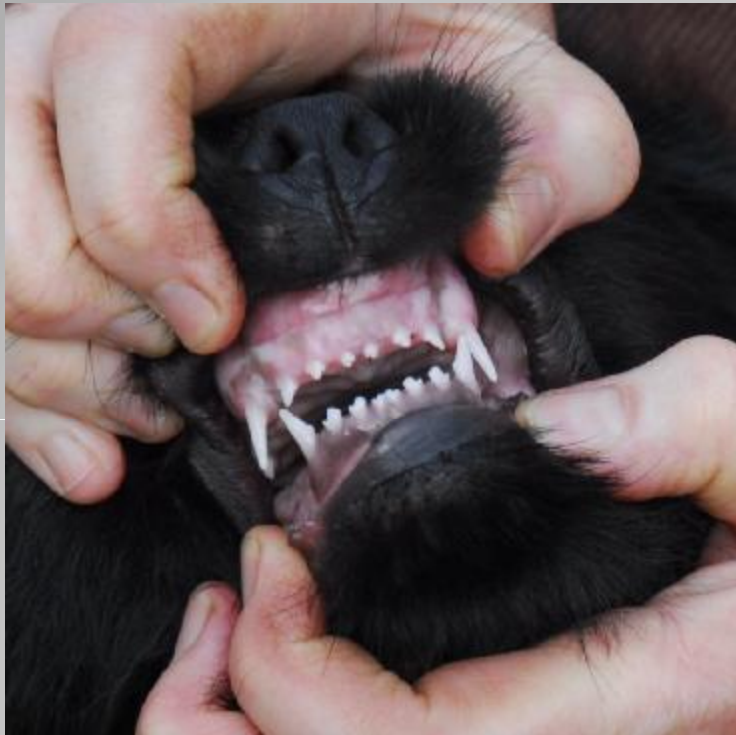The 9 week old Irish Wolfhound in the previous slide has

- jaws of more or less equal length
- but**
- a temporary disparity in the width

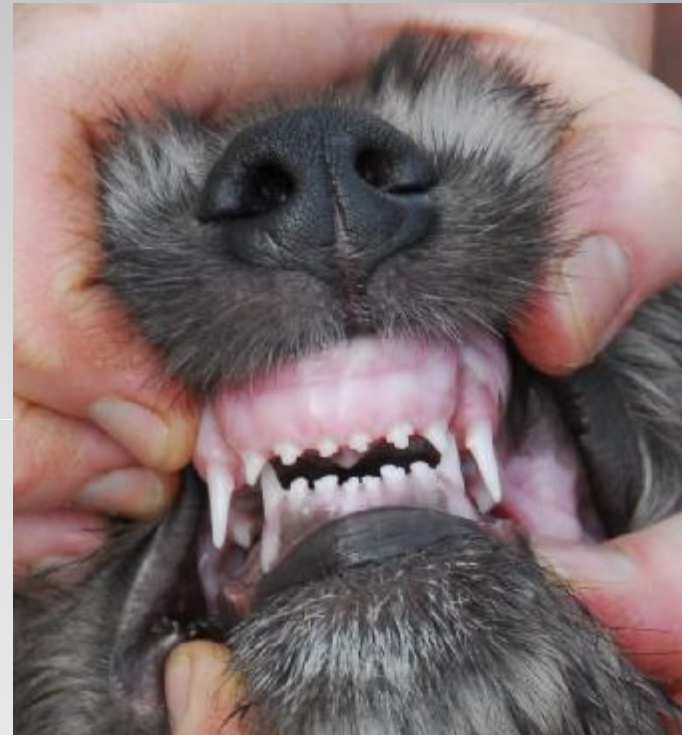This is not an unusual occlusion for an Irish Wolfhound puppy of this age

- However, we are hearing of increasing numbers of vets wishing to refer puppies to canine orthodontists, for what is almost always a temporary problem

What is "normal" for puppies?



9 week old pup with normal occlusion



9 week old pup with lingual displacement of the lower canines

Misplaced lower canines

are often seen in growing Irish Wolfhound puppies in both the **deciduous** and the **permanent** teeth

This can be due to any (or a combination) of the following:-

- a temporary disparity in jaw growth
 - teeth being in too upright a position
 - narrow lower jaw
- any/all of the above situations have the **potential** to change -
- longer upper, or shorter lower jaw
(maxillary prognathism/mandibular brachygnathism)
a true "overshot" jaw is usually evident by 8 weeks or so
- It is due to a genetic skeletal abnormality and **unlikely** to change



IWHG – Dentition Study



IRISH WOLFHOUND PUPPY FACTS

- Differential development considered normal - takes place in all areas of the body
- For the first 6 or 7 months, they experience incredibly rapid growth
- Skulls elongate considerably, consequently dental occlusion may alter
- Permanent lower canines usually start emerging after the upper ones - and at this stage, the lower jaw is often slightly shorter and narrower than the upper

OBSERVATIONS FROM THE STUDY

- Dental malocclusions not unusual during growth and often transient and variable

Leading experts in the field of canine dental surgery acknowledge that mild malpositioning of the jaws and teeth can be due to

- **“a temporary disproportionate relationship caused by an independent jaw growth surge” [1] and “if left on its own, there is a chance that the opposing jaw will soon experience its own surge in growth to return it to the correct relationship, if genetically coded to do so.”**
- As the puppy matures, the transient disparity in jaw growth often evens out **“with the mandible typically experiencing the later growth”**

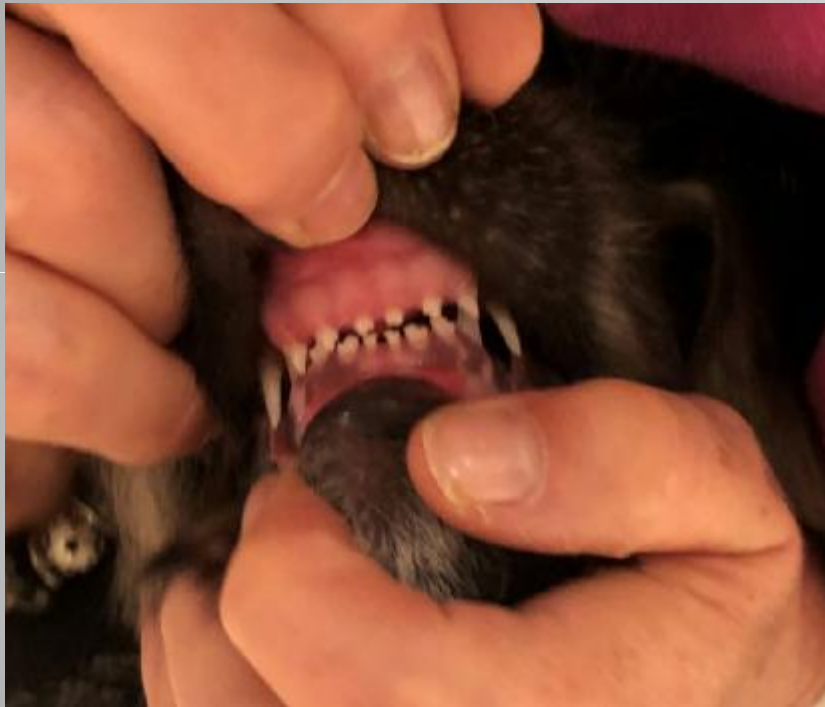One reason for this presentation

To discuss whether surgical intervention is necessary and appropriate, in giant breed puppies presenting with this condition

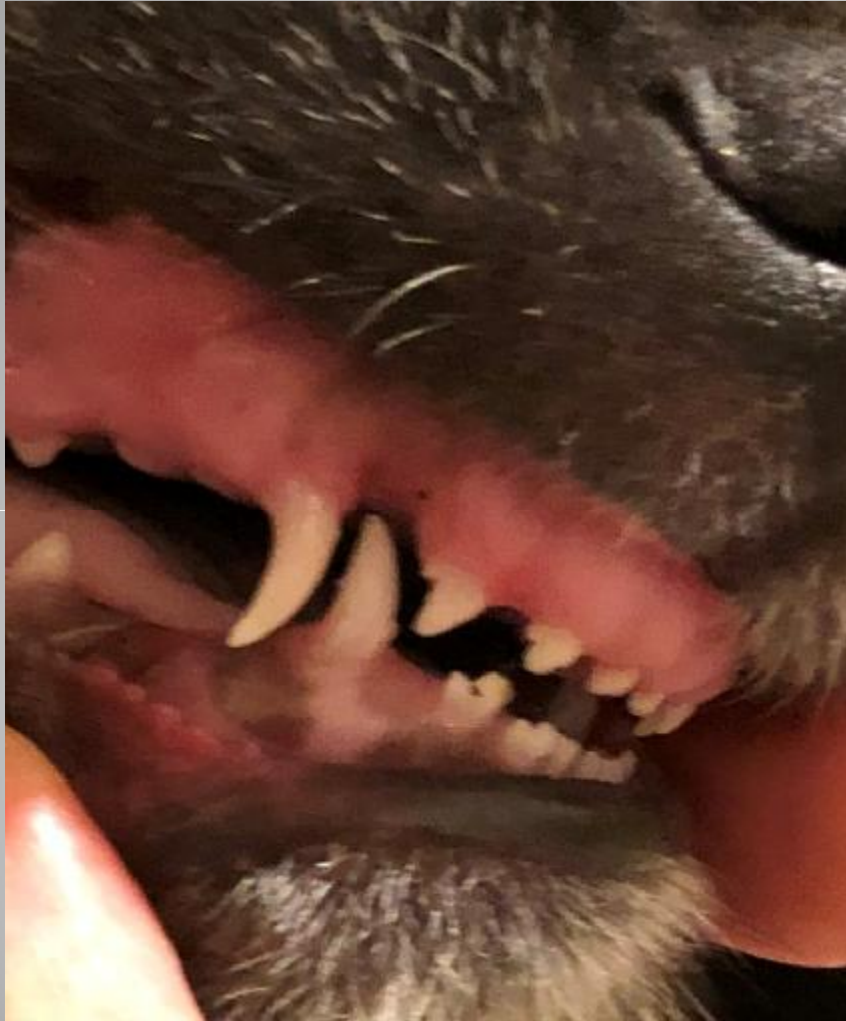or

whether conservative management is an acceptable alternative

If a 10 week old puppy of yours looked like either of these, would you agree to a vet removing both of the lower canines?



Another view of 10 week old puppy on the left of the last slide



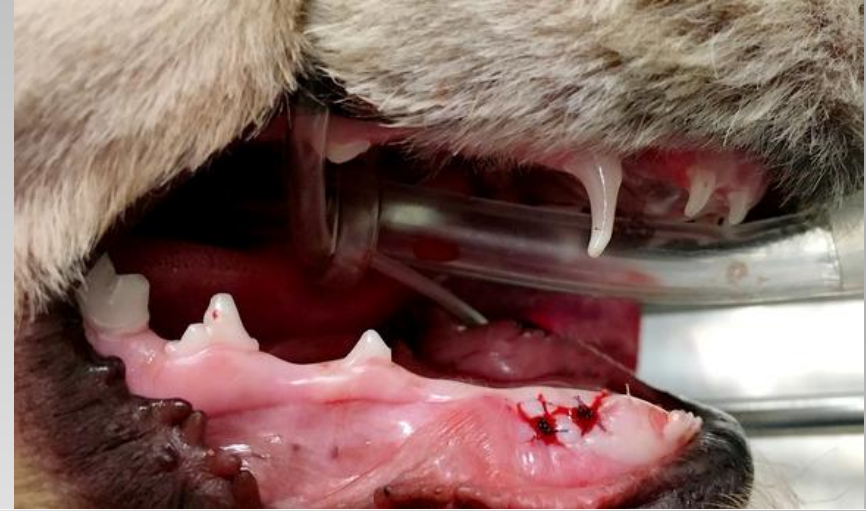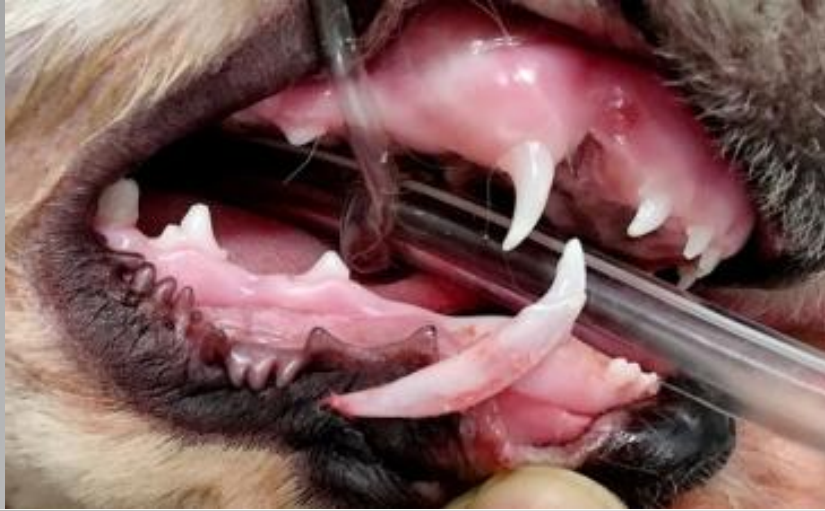OBSERVATIONS

- Incisors meeting in scissor bite
- Good relationship of maxilla and mandible
- Lower canine correctly positioned in front of the upper, with good maxillary diastema
- No indication of an overshot jaw, or skeletal deformity
- **Lower canines impinging on gum line, at this stage of growth..**

His occlusion appears better than the puppy on the right in the previous slide, but this puppy underwent surgery at 10 weeks, to remove his deciduous lower canines

NB: The other puppy achieved correct alignment of her permanent teeth, without any intervention whatsoever.

So "Fangs" - or - No "Fangs"?



These pictures show a large breed puppy, (not an Irish Wolfhound) with a long foreface, whose lower canines were removed at 10 wks.

- The roots of these teeth are challenging to remove in one piece
- This delicate operation should only be performed by a specialist
- Tooth buds for the permanent teeth are already present and lie adjacent to these roots
- Unintentional disturbance could jeopardise correct eruption of the permanent teeth- necessitating further surgical intervention.
- Mouths in particular harbour many potentially pathogenic bacteria, so the risks of infection are high



IWHG – Dentition Study



- It is actually advised that surgery to remove misplaced lower canines should “ideally” be performed between 4 and 8 weeks of age – and not later than 12 weeks!
- This would almost certainly mean that the “ideal” age at which to perform such surgery would be while the puppy was still with their breeder.

So why might a vet suggest removing healthy "baby teeth" in a 10 week old puppy?

According to some veterinary dental specialists, the rationale behind this is threefold:-

- (a) to alleviate pain (from the lower canines impacting on the upper gums/palate)
- (b) to prevent adverse dental interlock
- (c) to enable the permanent teeth to erupt correctly



Enabling the permanent teeth to erupt correctly

“Wiggs Veterinary Dentistry” manual states:-

- **“When considering deciduous extraction, the owner should always be informed that while reasonable precautions are being taken to minimize potential damage to the permanent teeth, problems may still occur.**
- **These vary from minimal pitting of the enamel to major structural defects, to complete relocation of the tooth.”**

If this surgery didn't go completely to plan, it could result in irreparable damage to the permanent teeth

- **temporary malocclusions occur when the jaws grow at varying rates during development.** *(this statement is based on the “average” dog – it is not even specific to giant dolichocephalic breeds)*

Therefore – ANY dog, of ANY breed, can exhibit a temporary malocclusion while growing

- furthermore, when referring to this procedure, it is also acknowledged that:-

- **“If the hereditary influence is for a specific jaw malocclusion, this procedure will not change the outcome.”**

**Removal of deciduous teeth could be deleterious to permanent teeth
Pup might achieve a normal adult occlusion (with or without surgery)
Point (c) is therefore largely redundant as a meaningful consideration**

Adverse Dental Interlock

occurs when the occlusion of the teeth traps the jaws together
either because

(a) the teeth have formed holes or pits in the gums or palate

or

(b) the teeth themselves interlock incorrectly and prevent the jaws from meeting comfortably

- The concern is that by remaining in place, misaligned lower canines could have an undesirable effect on jaw development
- It is suggested that misaligned "baby" teeth are capable of interfering with the development of the jaws and may therefore alter their skeletal structure
- This may be a possibility in small or medium breeds, but can these small teeth, designed to naturally be jettisoned by 4 months, have such a monumental effect on the bony development of a **giant breed** puppy's jaws?

Adverse dental interlock?

An Irish Wolfhound puppy's head lengthens by at least 4 inches, between the ages of 3 and 6 months



Is it realistic to suggest that teeth in the process of being shed, might potentially prevent a giant, dolichocephalic breed puppy's jaw from growing?

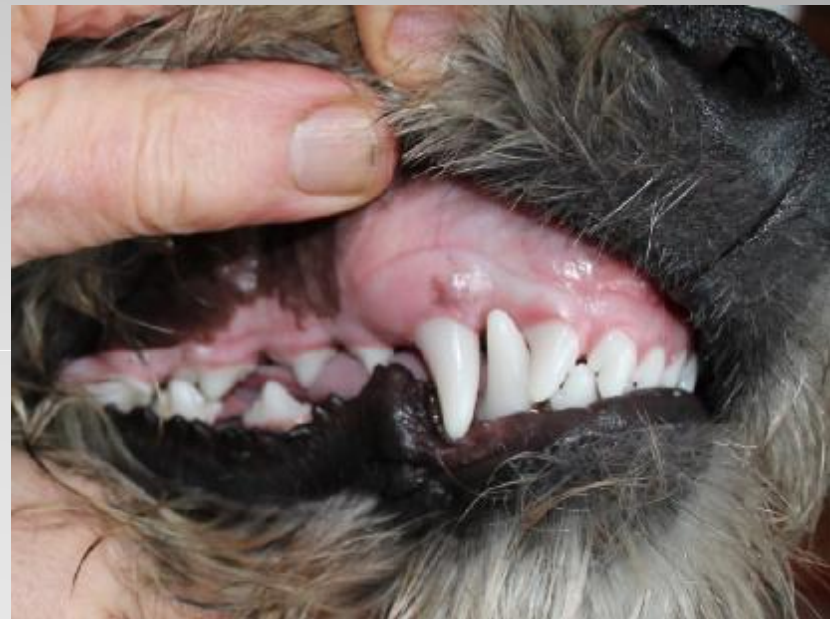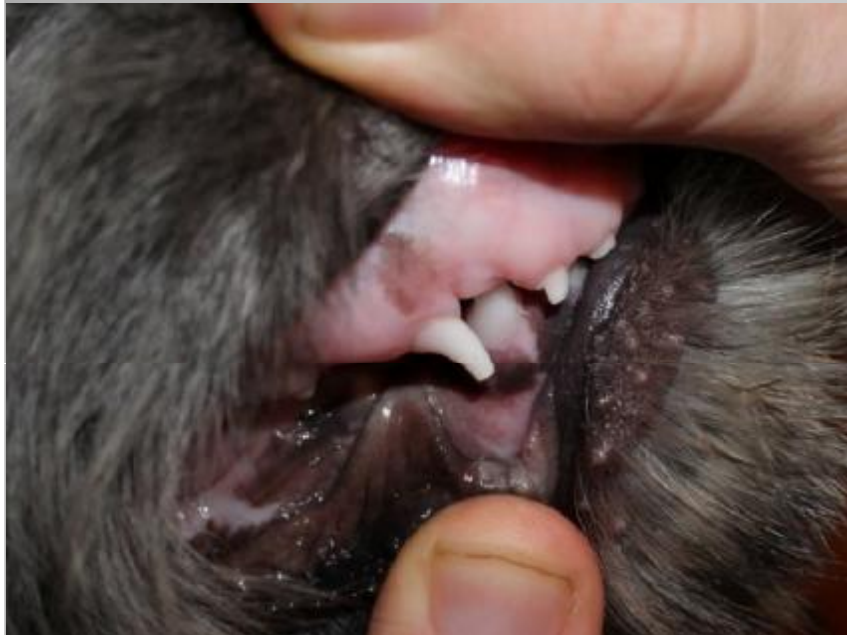Based on

- information documented by canine dental experts
- evidence contained in our survey forms and the photographs submitted
- the rapid jaw growth, with consequent & ongoing movement of the teeth

it does not appear that impinging deciduous teeth are retained in the same position long enough, to cause significant disruption to the growth of the jaws of an Irish Wolfhound.

Does a malocclusion of the deciduous teeth always lead to a malocclusion of the permanent teeth?

- 13 week old puppy with severe malocclusion of right lower canine
- The same puppy at 6 months showing ideal occlusion



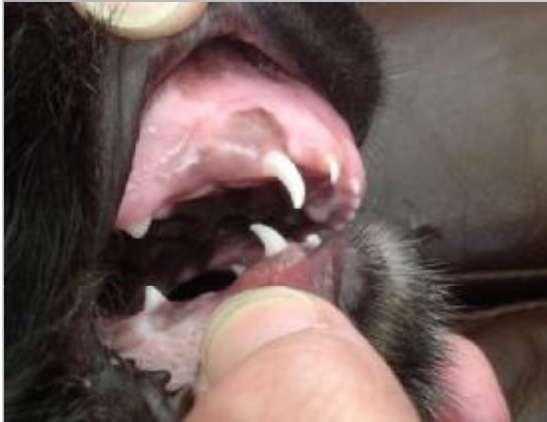This puppy did not undergo any surgery, it's simply the way he grew.

Information supplied by our survey shows that a puppy's deciduous occlusion, often has little bearing on the permanent occlusion

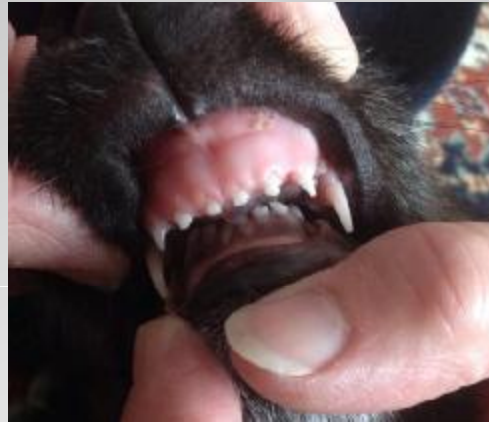Overshot (Mandibular Brachygnathism / Maxillary Prognathism)

A conclusive statement regarding adult dentition, cannot categorically be made based on looking at mild to moderate malocclusions of the deciduous teeth. Obvious exceptions are extreme cases - such as a severe difference in length and width of the jaws - as can be seen in a puppy with an overshot jaw, which we already know is a genetic condition.

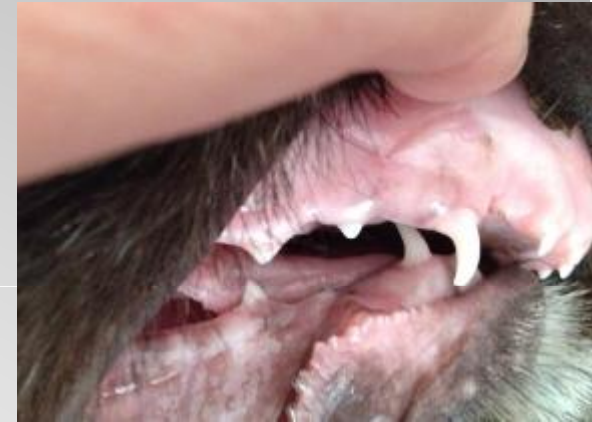10 weeks



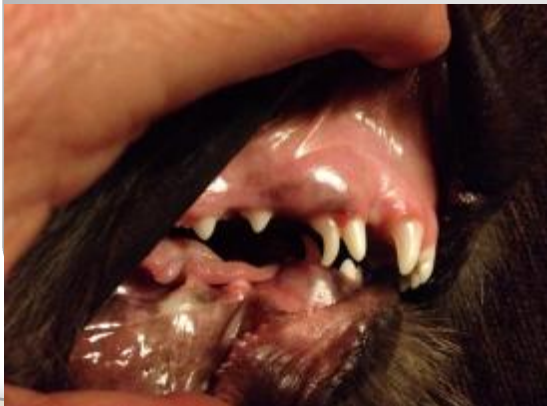10 weeks - front



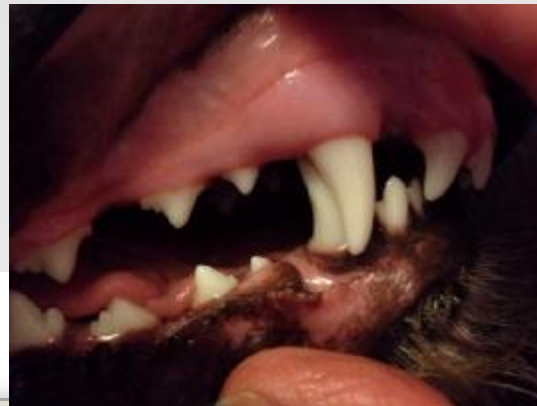15 weeks



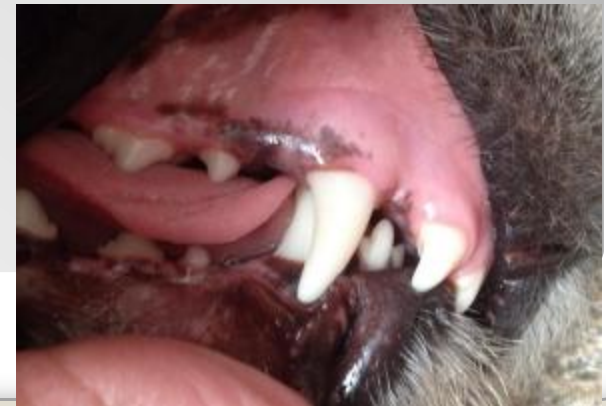20 weeks



8 months



11 months





IWHG – Dentition Study

THE OVERSHOT MOUTH (continued)



- Skeletal malformation, almost always obvious by the time the puppy is ready to go to his/her new home
- Genetic condition, can be inherited. Unwise to breed from animals with this condition - caution advised if breeding from littermates
- Occasionally seen in Irish Wolfhounds, varying degrees of severity and how it affects individuals. Not always possible to predict how severe the problem will be in adulthood
 - the previous slides show the lower jaw advanced considerably, in relation to the upper, between the ages of 10 weeks and 11 months
 - The hound shown is now 5 years old, fit and well. Owner reports no difficulty eating and no apparent discomfort
 - There has been little or no significant change in her occlusion since 11 months.
 - She hasn't undergone any interventional procedures
- Some hounds with this type of occlusion may require capping, removal, or repositioning of a tooth or teeth, to prevent pain. However, it should be borne in mind that no amount of surgery to remove, or attempt to realign the teeth, will correct a malformation of the jaw bones

So what about pain and soft tissue trauma?

- **No-one wants their puppy to be in severe discomfort**
- **Is this pain - transient? – variable? – manageable?**

Risks vs Benefits

Risks

- **Potential problems relating to GA's (esp. in sighthounds)**
- **Adverse side effects of opiates for many sighthounds**
- **Possibility for post-op pain and/or infection**
- **Possibility of further operations**

Benefits

- **Short term pain relief**

HOW DO I KNOW IF MY PUPPY IS IN PAIN?

Dr. Alexander Reiter, (Head of the Dentistry and Oral Surgery Service at the University of Pennsylvania School of Veterinary Medicine) advocates that if the puppy is still engaging in normal activities like eating, drinking, socialising, grooming and exploring, then it's unlikely there is a serious problem. However, he does go on to say, "If the dog isn't doing some of these things and the pain or discomfort is affecting his quality of life, then the puppy may need to see the vet."

- Some puppies, in breeds exhibiting **normal** growth patterns, will be in severe pain, especially if the lower canines are in the same position for 3-4 months and causing damage to the tissues of the mouth.
- Wolfhound pups have **exceptional** growth - prolonged, or consistent discomfort is much less likely
- The deciduous lower canines are in a state of flux - indentations in the gum or palate usually quickly heal over, sometimes on a daily basis, as the teeth advance forward and outward.
- Most animals (including ourselves) do not hold their mouths tightly shut when at rest – regardless of whether it is painful or not to do so.
- Teething in general can be painful, so as with any transient pain, is it best to attempt to manage it until resolved? - i.e. when the deciduous teeth are shed naturally

EARLY SURGICAL INTERVENTION - RISKS vs BENEFITS

It is important to weigh up the efficacy of pain management, against the possible complications that can arise from *any* surgery.

- Current research shows that removal of deciduous lower canines is **less than 20% effective** (in ANY breed) in promoting a beneficial effect on the eruption and occlusion of the permanent teeth.

With **no guarantee** that removing the deciduous lower canines prevents the need for further corrective procedures being necessary, then –

- cumulative effects of several surgeries at a young age and the potential for these to have a deleterious effect on heart function - in a breed prone to heart irregularities - should be a very serious consideration.

In addition -

- As sighthounds, Wolfhounds are often sensitive to both the anaesthesia and the opiates, widely used in canine surgery.
- GA's should be avoided unless **absolutely** necessary - **especially in Irish Wolfhounds – particularly in puppies.**

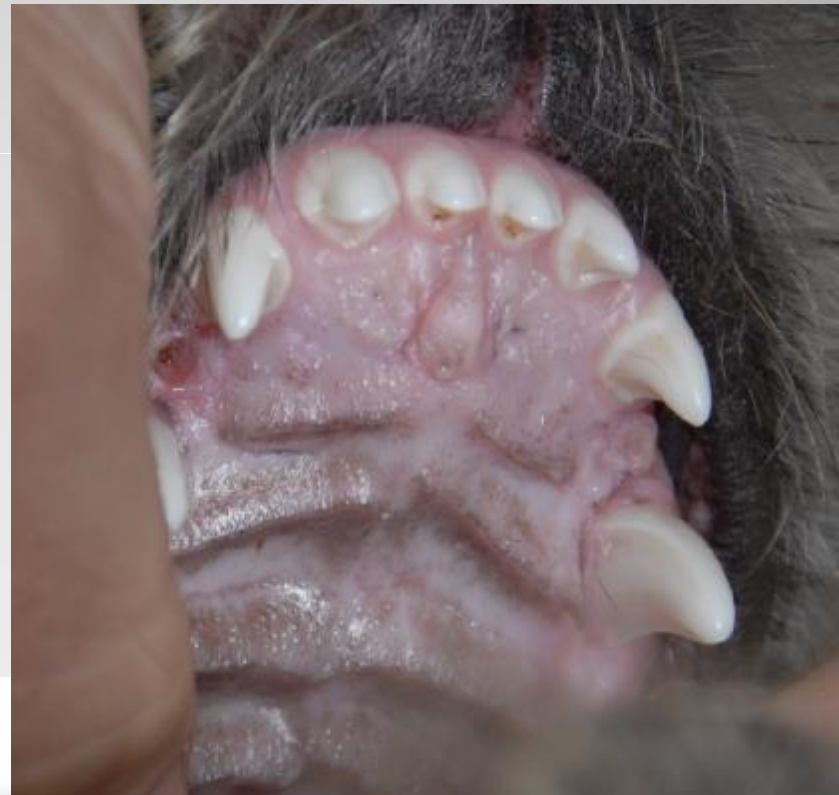The removal of healthy, misaligned deciduous lower canine teeth (**as opposed to retained teeth**) in a puppy of less than 5 months old, could therefore be considered unnecessary, unless the puppy is in **severe** discomfort.

Our evidence suggests that for Irish Wolfhound puppies, surgical intervention may be inappropriate and potentially detrimental to breed welfare.

What if the permanent lower canines are erupting incorrectly?

This slide shows a 6 month puppy, whose right lower canine is misplaced

- The gums and palate were carefully monitored for serious trauma, whilst the teeth and jaws continued to grow
- There is an indentation where the tip of the misaligned tooth has impinged on the gum line.
- Two healed pits on the gum line on the other side, where the left lower canine previously impinged, may also be seen.



“a removable orthodontic device for the treatment of lingually displaced mandibular canine teeth in young dogs” - otherwise known as:-

RUBBER BALL THERAPY

- Description of this technique was first published by Belgian vet, Leen Verhaert (DVM) some 20 years ago
- One of the least invasive and most successful tools we can use to help the lower canines attain their correct position
- Success rate for this therapy is not only comparable to conventional orthodontic techniques, it is also inexpensive and non-invasive
- Puppies are encouraged to carry or chew on a rubber ball, or Kong. (Not a tennis ball, as the surface is abrasive and can cause wear to the teeth) When the ball is held just behind the canine teeth, gentle outward force is applied on the lower canines, encouraging them to tip into the proper position as they erupt
- This technique is harmless (as long as the puppy is supervised and the correct sized ball or Kong is used)

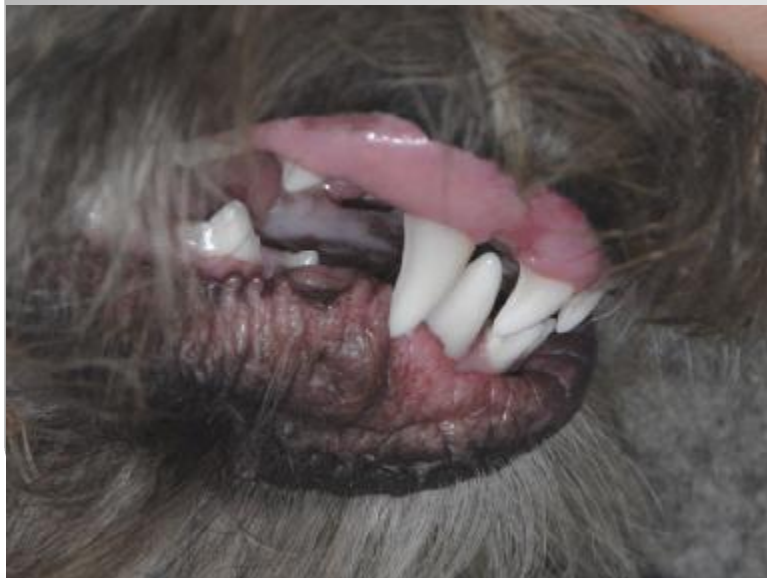Other correctional techniques, such as bite planes, tipping and applying extended teeth tips, which shed after a few weeks, require surgical intervention

- All of these require at least one GA
- As operations, the orthodontist may insist upon notifying the Kennel Club

- **Development of a puppy's mouth**

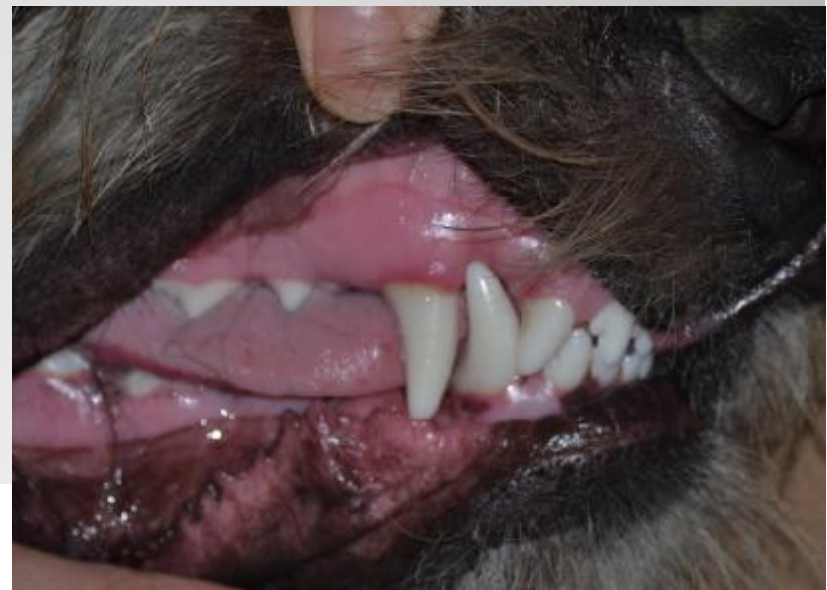6 month old puppy

These photos are of the same puppy in the previous slide. The permanent upper and lower canines are still growing. At this stage, the lower right canine is in line with the gum. As the teeth continue to erupt through the gums, the upper canines curve backwards and the lower canines flare outwards.



8 month old puppy

The same puppy, with the lower right canine now correctly fitting outside the upper gum. The bite is still a little "tight" but is acceptable. This puppy did not undergo any surgical intervention, neither was any form of therapy used, other than the usual chewing activities indulged in by healthy puppies!





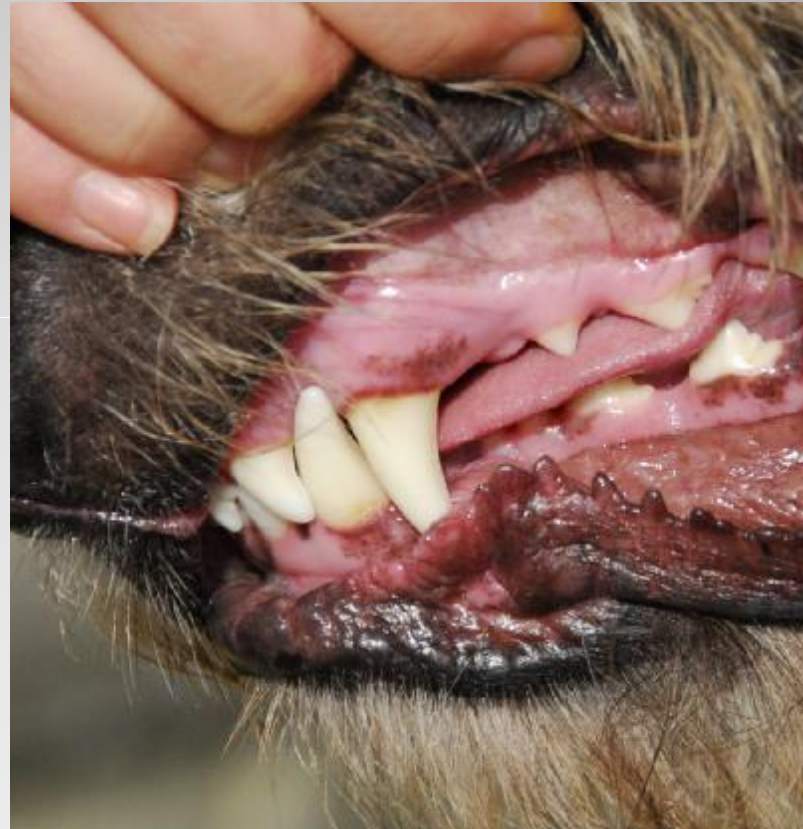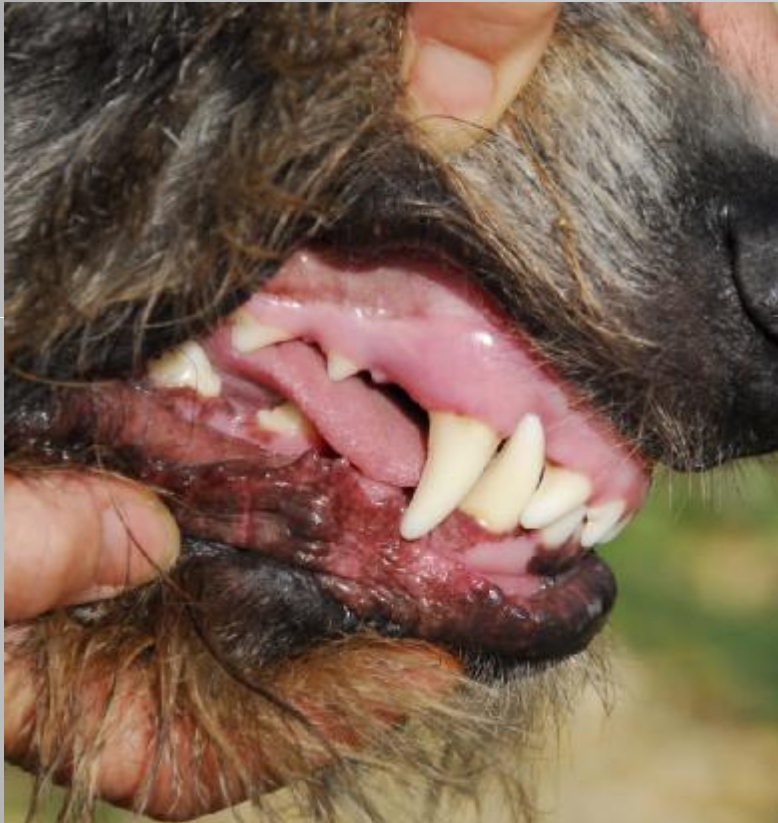IWHG – Dentition Study



- As with any aspect of Irish Wolfhound growth, there is a lot of variation in what can be considered “normal”.
- Most Wolfhounds’ mouths attain their final occlusion between 11 - 14 months.
Some hounds’ dental occlusions may continue to alter until 2 years of age.
- Young hounds should not be expected to have the dental occlusion of a mature adult

- The same puppy at 17 months

Both canines fitting comfortably and correctly with the mouth occluding in a scissor bite



CONCLUSIONS

The hyper-brachycephalic breeds are not expected to conform to the average. We believe that a case should also be made for our breed, whose conformation tends towards the opposite extreme.

Further assistance is required

- To enable us to put forward a robust argument to the Kennel Club, to exempt Wolfhounds under the age of 18 months from the current "Breed Watch" point
- To make a case to veterinary dental specialists, demonstrating that Irish Wolfhounds have distinct growth patterns, which do not conform to the "norm"

As owners and breeders, you can help by completing the short questionnaires on the IWHG website

"First do no harm" is regarded as an important injunction against the temptation to over-treat and is one of the principal precepts of bioethics for all medical practitioners.

A natural development, (*with appropriate pain management if/when required*) - especially if it results in a good occlusion - is surely preferable to opting for several surgeries
to potentially arrive at the same end result



Fangs for listening!